



**PATIENT**

Eleanor Thompson

**PRESENTING CLINICAL SIGNS**

History: Weight loss. Heart murmur, grade 3/6, systolic.  
 -Current medications Gabapentin, Incurin.

**SPECIES**

Canine

**ELECTROCARDIOGRAPHIC FINDINGS** \*Note: Single lead ECGs are evaluated as a rhythm strip. Morphology/MEA cannot be definitively commented on.

A single lead ECG is available; 50mm/s, 10mm/mV. The average heart rate is 155bpm with a largely regular rhythm. The rhythm is sinus in origin, with a p for every QRS complex and vice versa. The P and QRS morphologies are positive. No ectopic beats, pauses or dysrhythmias observed.

**BREED**

Bull Mastiff

ECG diagnosis: Normal sinus tachycardia.

**SEX**

Female Spayed

**ECHOCARDIOGRAM FINDINGS**

2D, m-mode, color flow and doppler imaging is available. Severe left ventricular dilation with decreased systolic function. Decreased LV wall thickness with increased sphericity. Severe left atrial enlargement. The mitral valve appears normal in form and function, with no obvious prolapse into the left atrial lumen. Moderate eccentric mitral regurgitation secondary to annular stretch. Decreased MR velocity. Mild tricuspid regurgitation. Mild right atrial and ventricular dilation. The aortic valve is normal in morphology and mobility. No subvalvular ridge present; normal LVOT velocity. No aortic insufficiency. Normal pulmonic valve with trace pulmonic insufficiency seen. No pericardial or pleural effusion noted. No obvious cardiac tumors.

**AGE**

10 years

**WEIGHT**

99lbs

**CARDIAC CHART**

**INTERPRETED BY**

Maggie Machen  
 Lamy, DVM, DACVIM  
 (Cardiology)

**IMAGING PERFORMED BY**

Sara Hansen

**HOSPITAL NAME**

West Eugene Animal  
 Hospital

**REFERRING VET**

Dr. Larsen

**INVOICE**

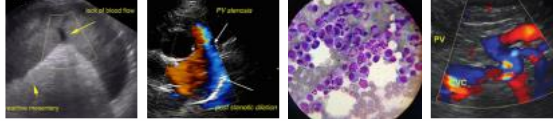
26790

**DATE**

10/7/22

CANINE CARDIAC PARAMETERS	MR VMAX (m/s)	TR VMAX (m/s)	LA/AO (Boon method)	LA/AO (Heart Base; Swe)	FS (%)	EF (%)	EPSS (cm)	
NORMAL PARAMETER	4.5-5.5	<2.7	1.3	<1.6	28-40	40-100	<0.6	
PATIENT	4.2	NM	1.6	2.2	15	32	1.6	
CANINE CARDIAC PARAMETERS	HR (BPM)	AV VMAX (m/s)	PV MAX (m/s)	BODY WEIGHT (kg)	LA 2D short axis Base view (cm)	LVIDd Avg; 2D and m-mode short axis (cm)	LVIDs Avg; 2D and m-mode short axis (cm)	
NORMAL PARAMETER	50-100	0.7-1.7	0.7-1.6	BELOW	BELOW	BELOW	BELOW	
PATIENT	NM	1.1	0.5	44.9	5.3	6.8	5.8	
*Normal chamber parameters expressed as a mean value (SD)					3	1.27 (5.3)	2.46 (2.46)	1.36 (5.5)
<b>BODY WEIGHT DEPENDENT PARAMETERS</b>					5	1.40 (4.5)	2.74 (5.2)	1.60 (4.7)
					10	1.50 (3.8)	3.27 (3.5)	2.06 (3.1)
					15	1.83 (2.0)	3.71 (2.4)	2.43 (2.1)
					20	2.02 (1.9)	4.14 (2.2)	2.80 (2.0)
					25	2.18 (2.4)	4.48 (2.9)	3.10 (2.5)
					30	2.33 (3.3)	4.83 (3.9)	3.39 (3.4)
					35	2.48 (4.3)	5.17 (5.0)	3.69 (4.5)
					40	2.62 (5.2)	5.48 (6.1)	3.96 (5.4)
					50	2.88 (7.1)	6.07 (8.3)	4.46 (7.4)

Adapted from June Boon, Veterinary Echocardiography, 1998  
 Rishniw M and Hollis NE, J Vet Intern Med 2000; 14:429-435  
 Hansson et al, Vet Rad and Ultrasound 2002  
 Bonagura et al. Echocardiography: principles of interpretation, Vet Clin North Am 15:1177, 1995



**PATIENT**

Eleanor Thompson

**SPECIES**

Canine

**BREED**

Bull Mastiff

**SEX**

Female Spayed

**AGE**

10 years

**WEIGHT**

99lbs

**INTERPRETED BY**

Maggie Machen  
Lamy, DVM, DACVIM  
(Cardiology)

**IMAGING PERFORMED BY**

Sara Hansen

**HOSPITAL NAME**

West Eugene Animal  
Hospital

**REFERRING VET**

Dr. Larsen

**INVOICE**

26790

**DATE**

10/7/22

**INTERPRETATION OF THE FINDINGS & FURTHER RECOMMENDATIONS**

Unfortunately, this patient has significant cardiomyopathy and systolic dysfunction. This is causing dilation and volume overload of both the left and right heart resulting in insufficiency of the mitral and tricuspid valves. The severity of dysfunction and pump failure is severe, and the patient is at high risk for decompensating into congestive failure. Patient will always be at risk for right and/or left-sided CHF, development of arrhythmias/syncope and/or sudden death going forward. The ECG is unremarkable, although a sinus tachycardia may suggest early decompensation.

Systolic failure can be primary in nature (DCM) or secondary to taurine deficiency, myocarditis, hypothyroidism, tachycardia-induced cardiomyopathy, or infiltrative disease such as lymphoma. While primary disease is likely, consider testing for primary causes that may be treatable. A troponin (cTnI) level can be submitted to further investigate infiltrative/inflammatory contribution (myocarditis). Additionally, a taurine level may be helpful (screen for malabsorption issue), and a thorough diet history given the recent correlation with grain free/boutique brand/exotic ingredient diets. Finally, further systemic evaluation for underlying infiltrative contribution such as neoplasia is also reasonable (abdominal ultrasound, etc.).

Regardless of cause, prognosis is guarded to poor at this stage in the disease process, with an average survival time of <6 months. The only treatable cause of systolic failure is diet/taurine deficiency, which is uncommon on commercially formulated dog foods. If the diet is of concern, highly recommend immediate diet change and taurine supplement regardless of blood taurine results. Please see the FDA website for more information.

Immediate institution of full cardiac supportive medications is recommended as below due to high risk for decompensation. This includes low dose therapy. Cases of systolic failure are at high risk for malignant tachyarrhythmias (such as VT or rapid AF) and sudden death, and this should be expressed to the owner. Activity restriction is advised, and a baseline ECG recommended.

Elective anesthesia is not advised due to high risk for complications.

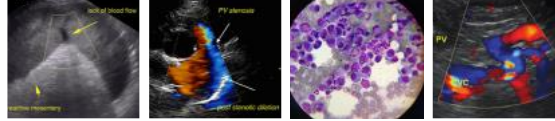
Omega fatty acid supplementation and mild salt restriction may be of some long-term benefit. Monitor for development of a cough, worsening labored breathing, abdominal distention, exercise intolerance or collapse episodes in the future. Monitoring of sleeping breathing rates at home is recommended to assess response to medications and recurrence of CHF in the future.

**PLAN:**

Baseline BP/ECG recommended. Initiate aldosterone antagonist Spironolactone 1-2mg/kg PO q12h. Institute furosemide 1mg/kg PO q12h. Institute Pimobendan 0.3mg/kg PO q12h. Institute taurine 1000mg PO q12h. Diet history/change as discussed.

Monitor a renal panel and blood pressure in 1-2 weeks to ensure tolerance. If BP >130mmHg, institute ACEI 0.5mg/kg PO q12h. Consider cTnI, taurine level, AUS as discussed above.

A recheck echocardiogram is recommended in 4-6 months to screen for progression, sooner if clinical issues arise in the interim.



**PATIENT**

Eleanor Thompson

**SPECIES**

Canine

**BREED**

Bull Mastiff

**SEX**

Female Spayed

**AGE**

10 years

**WEIGHT**

99lbs

**INTERPRETED BY**

Maggie Machen  
 Lamy, DVM, DACVIM  
 (Cardiology)

**IMAGING PERFORMED BY**

Sara Hansen

**HOSPITAL NAME**

West Eugene Animal  
 Hospital

**REFERRING VET**

Dr. Larsen

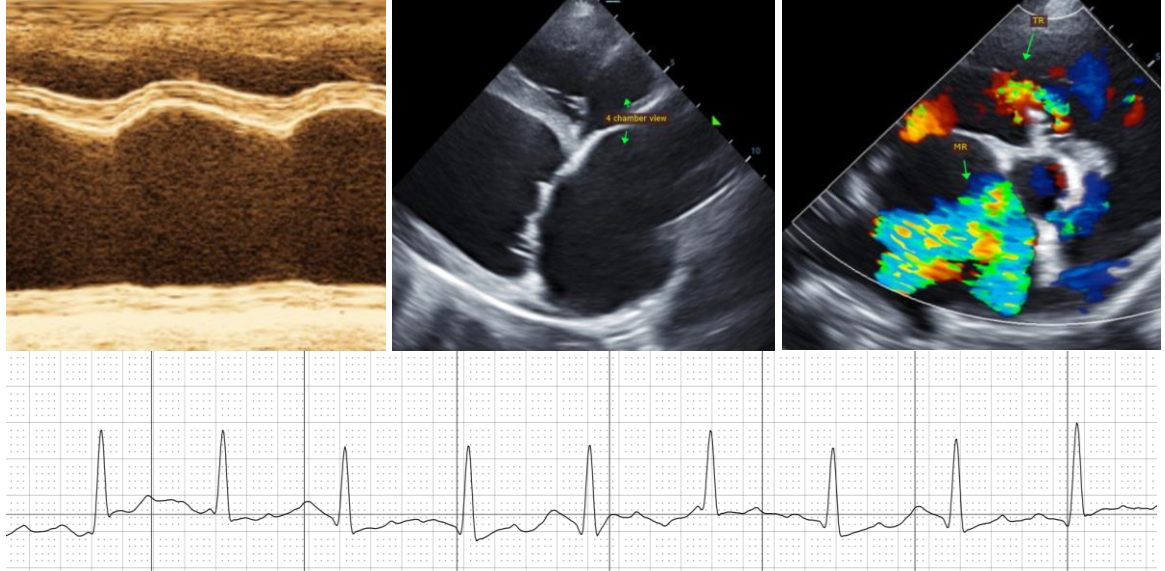
**INVOICE**

26790

**DATE**

10/7/22

**IMAGES**



The information and recommendations provided are based on the images presented by the referring veterinarian. No evaluation can be communicated regarding pathology that was not visible in the image/video clips provided.

Thank you for this referral. This report was generated using transcription software, and minor dictation errors may be present. If the clinical or image interpretation does not parallel your findings or if I can be of any further assistance, please contact me.

**Maggie Machen Lamy, DVM**  
 Diplomate of the American College of Veterinary Internal Medicine (Cardiology)  
 info@sonopath.com